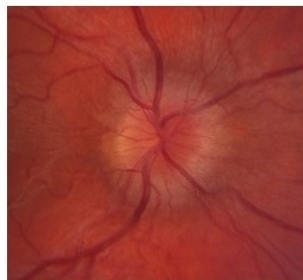

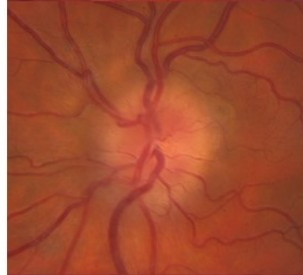
Modified Frisen Scale for Grading Papilloedema

Key features of each grade are marked with an asterisk (*)



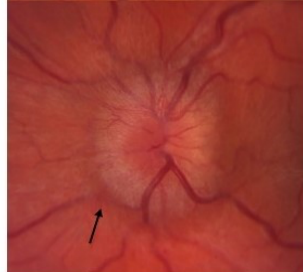
Grade 1

- Grayish C-shaped halo surrounding the disc*
- Sparing of the temporal disc margin
- Radial nerve fiber striation disruption



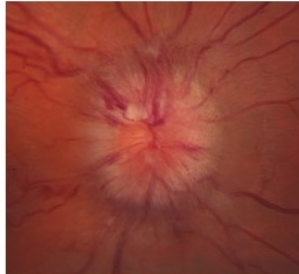Grade 2

- Halo becomes circumferential*
- Nasal border elevation
- No major vessel obscuration



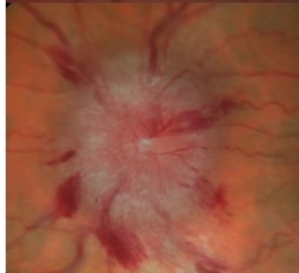
Grade 3

- Obscuration of at least one vessel *leaving the disc** (arrow)
- Elevation of all borders
- Circumferential halo



Grade 4

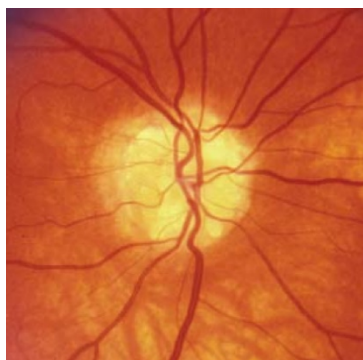
- Obscuration of a major vessel *on the disc**
- Complete elevation including the cup
- Circumferential halo



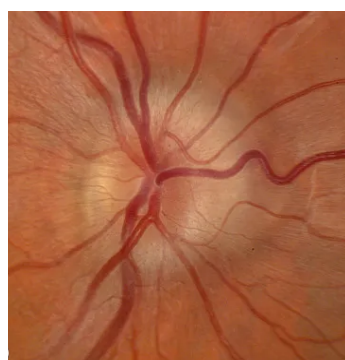
Grade 5

- Obscuration of all vessels on the disc *and leaving the disc**
- All features of Grade 4

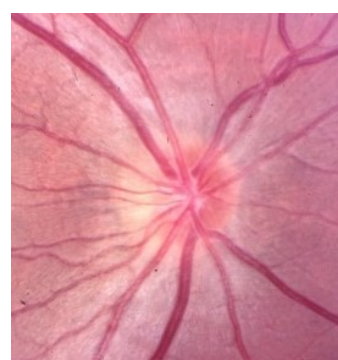
Pseudopapilloedema example images



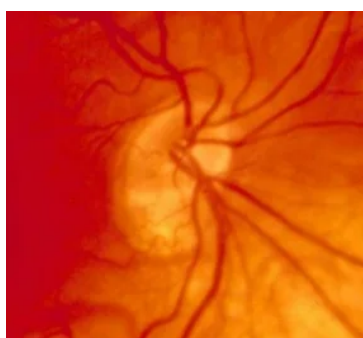
Visible ONH Drusen



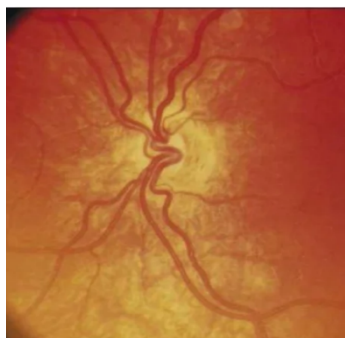
Buried ONH Drusen



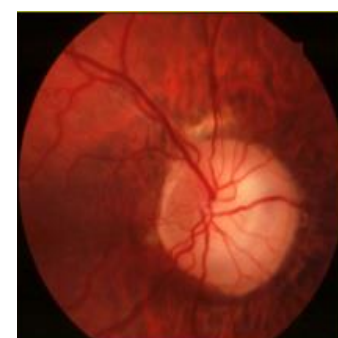Congenitally Crowded Disc



Tilted Disc



Optic Nerve Hypoplasia



Megalopapillae